

INTRODUCTION

Primary Bone Regeneration (P.B.R.) is a mechanism of natural bone healing leading to consolidation of two bone segments in 6 weeks. In Implant-Prosthodontics P.B.R. implants let the patient have quicker prosthetic rehabilitation also in case of severe bone atrophy and after guided bone regeneration. In fact with PBR implants it's possible to load them just after 45 days from implants insertion. This depends on primary intention bone healing with direct formation of bone tissue close in contact with implants and without interposition of connective tissue. The aim of this study was to evaluate osseointegration in early loaded P.B.R. implants inserted together with bone grafts in atrophic alveolar ridges.

MATERIALS AND METHODS

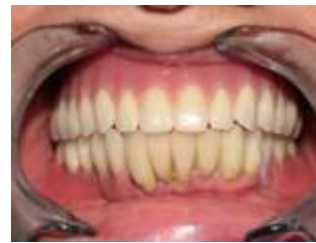
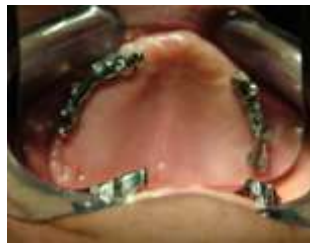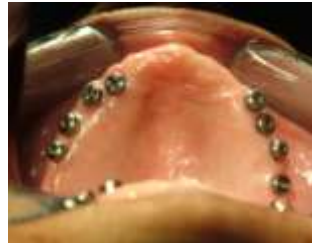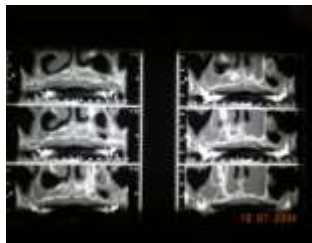
In our Prosthodontics Dept., Sapienza University of Rome, from November 2004 to October 2007 we selected 24 patients (both sexes, 42 years mean age, well healthy, no smokers) having maxillary and mandibular partial atrophic alveolar ridges and asking for implant supported prostheses. We inserted 78 rot ormer P.B.R. implants (TMI®, Pressing Dental, San Marino, Italy) together with a bone graft material (BioOss, Geistlich). Minimum implant diameter was 3.75mm and minimum length was 10.5mm. The primary implant stability was estimated by RFA. When the ISQ resulted ≥ 57 value, in the 2nd stage surgery, they were early loaded (1.5 months from surgery). The ISQ values were subsequently estimated every month until the 6th month, then at 9 and 12 months. The endoral X-rays have been executed to 0, 2, 6, 9 and 12 months.

RESULTS

In the 2nd stage surgery, a complete bone defect filling was observed in all the cases except one that was characterized by partial bone defect filling (greater than 50% and without flap dehiscence). The most significant ISQ values increase, was observed in the first 2 months; a further ISQ value increasing was observed until the 3rd-4th month and successively the ISQ values levelled on constant shares. At the end of the second month just 6 implants (7.7%) of 5 different patients didn't show 57 ISQ value. Among these implants, 2 showed clinical mobility (M) in early time (third and fourth month) and they were removed and indicated like failures. The endoral X-ray didn't show any change of the marginal bone level. Clinical and X-ray results analyzed with T-Student test were statistically significant ($P < 0.005$).

CONCLUSIONS

The timing of bone tissue healing around TMI implants overlap timing of a simple fracture of the jaw bones. These results showed as early loading of PBR implants inserted together bone grafts seems to be a valid technique to restore atrophic alveolar ridges shortening healing time and having quicker clinical case resolution.



REFERENCES

- Cornellini R, Barone A, Covani U. Connective tissue grafts in postextraction implants with immediate restoration: a prospective controlled clinical study. *Pract Proced Aesthet Dent.* 2008 Jul;20(6):337-43.
- Esposito M, Grusovin MG, Achille H, Coulthard P, Worthington HV. Interventions for replacing missing teeth: different times for loading dental implants. *Cochrane Database Syst Rev.* 2009 Jan 21;(1):CD003878.
- Friberg B, Raghoobar GM et al. A 5-year prospective multicenter study on 1-stage smooth-surface Branemark System implants with early loading in edentulous mandibles. *Int J Oral Maxillofac Implants.* 2008 May;23(3):481-6.
- Lai HC, Zhang ZY, Zhuang LF, Wang F, Liu X, Pu YP. Early loading of ITI implants supporting maxillary fixed full-arch prostheses. *Clin Oral Implants Res.* 2008 Nov;19(11):1129-34.
- Malchiodi L, Quaranta A, Scarano A, Quaranta M. Jaw reconstruction with grafted autologous bone: early insertion of osseointegrated implants and early prosthetic loading. *J Oral Maxillofac Surg.* 2006 Aug;64(8):1190-8.
- Mannai C. Early implant loading in severely resorbed maxilla using xenograft, autograft and platelet-rich plasma in 97 patients. *J Oral Maxillofac Surg.* 2006 Sep;64(9):1420-6.
- Piattelli A, Corigliano M, Scarano A, Quaranta M. Bone reactions to early occlusal loading of two-stage titanium plasma-sprayed implants: a pilot study in monkeys. *Int J Periodontics Restorative Dent.* 1997 Apr;17(2):162-9.
- Sennerby L, Gottlow J. Clinical outcome of immediately/early loading of dental implants. A literature review of recent controlled prospective clinical studies. *Aust Dent J.* 2008 Jun;53 Suppl 1:S82-8.

3389

CLINICAL AND HISTOLOGICAL EVALUATION OF ATROPHIC MAXILLARY RIDGES IMPLANT REHABILITATION

I. VOZZA*, S. ROSSI, A.M. CARPIO, E. NICOLINI and G. POMPA

Dental School, Prosthodontics Department, "La Sapienza" University, Rome, Italy

INTRODUCTION

The latest and new indications about implant surgery and the constant introduction on the market of new components and methodologies, go hand in hand with the ever-increasing demand from our patients for a quicker and quicker functional rehabilitation. Primary Bone Regeneration (P.B.R.) is a mechanism of natural bone healing leading to consolidation of two bone segments in 6 weeks. In Implant-Prosthodontics P.B.R. implants let the patient have quicker prosthetic rehabilitation also in case of severe bone atrophy and after guided bone regeneration. In fact with PBR implants it's possible to load them just after 45 days from implants insertion. This depends on primary intention bone healing with direct formation of bone tissue close in contact with implants and without interposition of connective tissue. The aim of this study was to evaluate early loading of PBR (Primary Bone Regeneration) implants inserted together with bone grafts in atrophic maxillary ridges.

MATERIALS AND METHODS

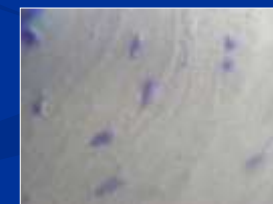
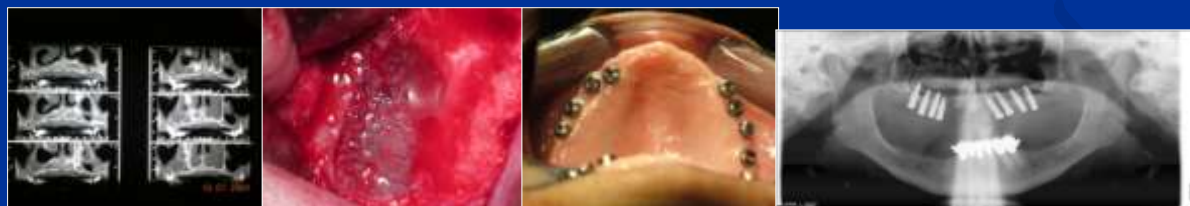In our Prosthodontics Dept., Sapienza University of Rome, from November 2004 to June 2007 a sinus lifting was performed in 8 patients (56 years mean age, male gender, initial bone height of 1.5 -2 mm and bone width of 5 mm) asking for a fixed implant-supported rehabilitation. They signed an informed consent. In every patient 2 root former PBR implants (TMI®, Pressing Dental, San Marino, Italy) having 3.25 diameter and 10.5mm length were inserted together with a bone graft material (Physiograft®, Ghimas). 2.5 months after maxillary sinus augmentation one of the implants was retrieved and processed for undecalcified histology while the other one was loaded. The endoral X-rays have been executed to 0, 2, 6, 9 and 12 months.

RESULTS

From the histomorphometric analysis, the graft material residuals accounted for the 46.98% of the bioptical volume, marrow spaces for the 18.76% and bone for the 32.87% (new bone: 22.62%, native bone: 10.25%). Well-mineralized regenerated bone with lamellar parallel-fibred structure and Haversian systems surrounded the residual graft material particles. The measured BIC amounted to 16.94%. No connective tissue was observed at the implant boundary surface. From clinical point of view there was no implant failure at the 2nd stage; neither mobility nor bleeding on probing. The endoral X-rays showed a complete bone defect filling and no change of the marginal bone level was observed. Clinical and X-ray results analyzed with T-Student test were statistically significant ($P < 0.005$).

CONCLUSIONS

These results showed as early loading of PBR implants inserted together with bone grafts appears to be suitable for maxillary sinus floor augmentation, also in critical condition as minimal vertical bone height and shorter healing time.



REFERENCES

- Attard NJ, Zarb GA. Immediate and early implant loading protocols: a review of clinical studies. *J Prosthet Dent.* 2005 Sep; 94 (3): 242-58.
- Brochu JF, Anderson JD, Zarb GA. The influence of early loading on bony crest height and stability: a pilot study. *Int J Prosthodont.* 2005 Nov-Dec; 18 (6): 506-12.
- Cornellini R, Barone A, Covani U. Connective tissue grafts in postextraction implants with immediate restoration: a prospective controlled clinical study. *Pract Proced Aesthet Dent.* 2008 Jul;20(6):337-43.
- Esposito M, Grusovin MG, Achille H, Coulthard P, Worthington HV. Interventions for replacing missing teeth: different times for loading dental implants. *Cochrane Database Syst Rev.* 2009 Jan 21;(1):CD003878.
- Friberg B, Raghoebar GM. A 5-year prospective multicenter study on 1-stage smooth-surface Branemark System implants with early loading in edentulous mandibles. *Int J Oral Maxillofac Implants.* 2008 May-Jun;23(3):481-9.
- Malchiodi L, Quaranta A, Scarano A, Quaranta M. Jaw reconstruction with grafted autologous bone: early insertion of osseointegrated implants and early prosthetic loading. *J Oral Maxillofac Surg.* 2006 Aug;64(8):1190-8.
- Mannai C. Early implant loading in severely resorbed maxilla using xenograft, autograft and platelet-rich plasma in 97 patients. *J Oral Maxillofac Surg.* 2006 Sep;64(9):1420-6.
- Lai HC, Zhang ZY, Zhuang LF, Wang F, Liu X, Pu YP. Early loading of ITI implants supporting maxillary fixed full-arch prostheses. *Clin Oral Implants Res.* 2008 Nov;19(11):1129-34.
- Piattelli A, Corigliano M, Scarano A, Quaranta M. Bone reactions to early occlusal loading of two-stage titanium plasma-sprayed implants: a pilot study in monkeys. *Int J Periodontics Restorative Dent.* 1997 Apr;17(2):162-9.
- Sennerby L, Gottlow J. Clinical outcome of immediately/early loading of dental implants. A literature review of recent controlled prospective clinical studies. *Aust Dent J.* 2008 Jun;53 Suppl 1:S82-8.



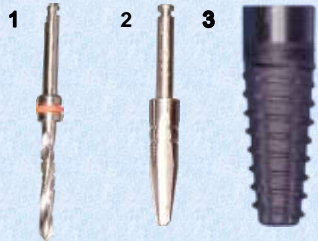
Histologic evaluation of a P.B.R. implant system: study in man

M. CORIGLIANO¹, **S. ROSSI**¹, A.M. CARPIO², and S. DI CARLO²,

¹International Academy of Implantoprosthesis and Osteoconnection, Rome, Italy, ²University of Rome Sapienza, Italy



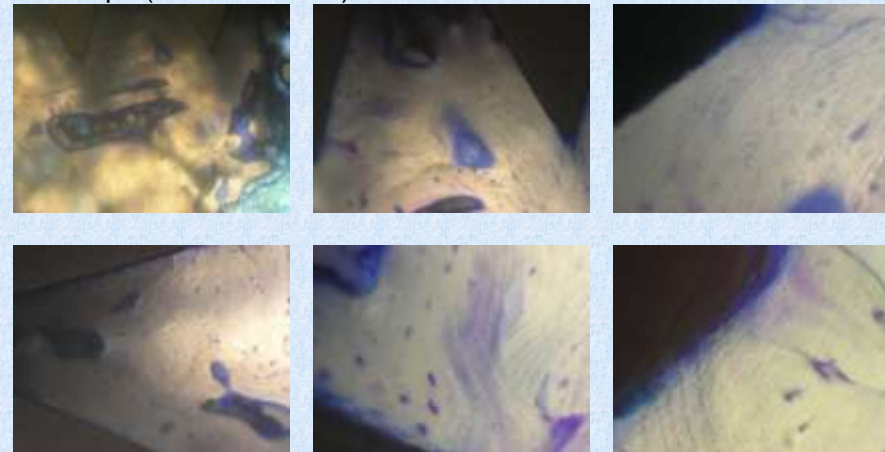
Objectives: The aim of this study was to obtain immediate bone reparation in only 6 wks, and to predict primary bone apposition without intermediate growth of the connective tissue.



TMI® Implant System is composed by:
Fig.1 Pilot Drill
Fig.2 Osteotom "UNICA"
Fig.3 Implant

Methods: We inserted 128 PBR (Primary Bone Repair) implants (TMI® Pressing Dental, RSM) into 42 patients of both genders, aged between 29 and 68 yrs. After 45 days, 25 implants were removed from their sites, carefully chosen so as not to endanger either the final prosthesis plan or the patient's health. The removed samples were embedded in resin (Tecnovit Kulzer), histologically prepared (EXAKT), and stained with **hematoxylin / eosin and methylene blue**. The same samples were then examined histologically under an optical microscope (Zeiss and Leitz) at 50-100-200-400X.

Histological images coloured with hematoxylin/eosin and methylene blue



Results: The quantity and the quality of the bone observed histologically in connection with the radicular titanium prostheses, following PBR, registered complete growth. The BIC (Bone Implant Contact), measured all around the removed implants, averaged 85%. Further, there were no necrotic zones associated with the resorption or substitution with connective fibrous tissue.



Surgical phases:
1 Drilling
2 Osteotomy with "UNICA"
3 Radicular prostheses insert

Conclusions: Our histologic analysis demonstrates that the PBR implant system is, without doubt, reliable. Actually, it permits a great deal of bone to support the progressive load of dental prostheses.

1. Schenk R.K. : *Histologie der Primären Knocheilung*. Verh. Dtsch ges pathol. 1974; 54: 8-12.
2. Corigliano M, Vrespa G, D'Addona A, Casolo F. : *Impianto a guarigione primaria*. Dental Cadmos 1994; 11: 60-72.
3. Piattelli A, Paolantonio M, Corigliano M, Scarano A. : *Immediate loading of titanium plasma-sprayed screw-shaped implants in man: a clinical and histological report of two cases*. J Periodontol 1997;68:591-597.
3. Corigliano M, Barlattani A, Gargari M, Ottria L, Andreana S. : *La riparazione ossea primaria in implantoprotesi; possibilità, tecnica ed applicazioni*. Quint Int 2002; 9/10: 359-370.
4. Cooper LF, Rahman A, Moriarty J, Chaffee N, Sacco D. : *Immediate mandibular rehabilitation with endosseous implants: simultaneous extraction, implant placement and loading*. Int J Oral Maxillofac Implants 2002;17(4):517-25.
5. Gherlone E, Albano F, Vrespa G, Falegatti G, Capuano A.: *Carico immediato su impianti post estrattivi immediati*. Implantologia 2004;1:25-37.
6. Forabosco A, et al.: *Impianti postestrattivi a carico immediato*. : Doctor Os 2006;17(1):188-190.



EARLY LOADED IMPLANT SUPPORTED OVERDENTURE: 3-YEAR FOLLOW-UP EVALUATION

S. ROSSI, I. VOZZA, A. GIOVANNETTI, M.P. BASILE, S. DI CARLO

Dental School, Prosthodontics Department, "La Sapienza" University, Rome, Italy

INTRODUCTION

Primary Bone Reparation PBR is a mechanism of natural bone healing determining consolidation of two bone segments in 6 weeks. In Implantology PBR implants consent to patient having prosthetic rehabilitation briefly because it is possible to load them just in 45 days from fixture insertion. This is possible thanking to first intention bone healing with direct formation of bone tissue in contact with implant and without interposition of connective tissue. Times of tissue reparation around implants are superimposable to times of a simple fracture of maxilla. The aim of this study was to evaluate perimplant marginal bone level on early loaded implants supporting overdenture.

MATERIALS AND METHODS

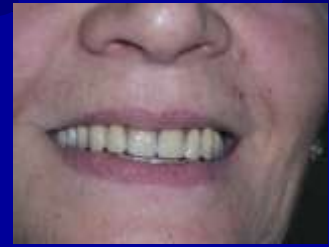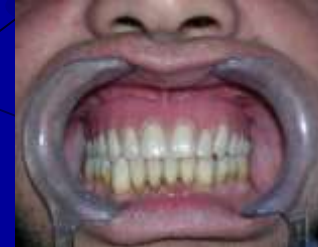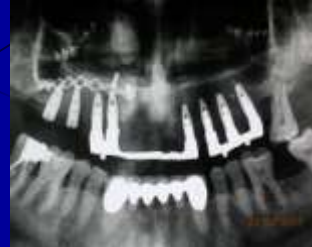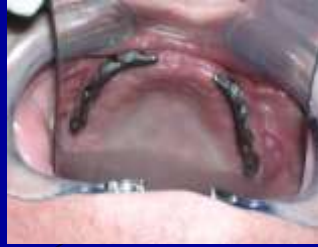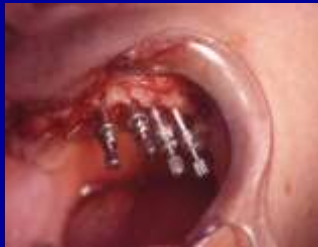In our Prosthodontics Department, La Sapienza University of Rome, from May 2001 to December November 2003, we selected 30 patients (both sexes, 49 years mean age, no smokers) having maxillary total edentulism and asking for fixed prosthetic rehabilitation. We inserted 128 root former implants (TMI, Pressing Dental, San Marino); they were early loaded after 45 days. Minimum diameter was 4.2mm and minimum length was 13mm. Before cementation of each final restoration we executed a periapical X-ray using a digital X-ray system (Den Optix, Gendex, Dentsply Int). The X-ray controls were executed after 1-3-6-9-12 months and then yearly.

RESULTS

Marginal bone levels were evaluated by 2 different operators using a computerised measure system (Vix-win 2000, Gendex, Dentsply Int). During the first year there was 0.28mm mean bone loss while during the next two years it was 0.17mm according to Albrektsson and Zarb implant success criteria (<1mm during the first year and <0.2mm during next years). X-ray results analyzed with T-Student test were statistically significant ($P < 0.005$).

CONCLUSIONS

Parameters for the valuation of Implantology success have to be established before discussing about obtained results by this experimentation. On the basis of this osseointegration definition, clinical studies have to be purposed to survey the implant stability under functional loading. In this order, it's necessary that during periodic controls implant mobility has to be evaluated and radiographic examinations have to be executed in a reproducible way for determining the state of perimplant bone tissue health. The implant success is evaluated on the following criteria by Albrektsson and Zarb: 1) the not splinted implant has to be clinically immovable; 2) on the X-ray no perimplant radiotranslucency marks have to be present; 3) vertical bone loss has to be lower than 1mm during the first year of loading and lower than 0.2mm yearly in the following years; 4) each implant has to be without marks or persistent and/or not reversible symptoms, for example, pain, infections, neuropathies, paresthesia or penetration into the mandibular canal; 5) prosthetic restoration has to satisfy function and aesthetics. On these preliminary remarks, in the anterior upper and lower sectors it should occur a success rate of 90% and 85% on long time, respectively, after 5 and 10 years; in the posterior sectors these percentages have to be about 85% after 5 years and 80% after 10 years. The obtained results from this experimentation are encouraging, fully respecting implant success criteria by Albrektsson and Zarb. These results showed as early loaded implants supporting overdenture are clinically and radiographically well osseointegrated.



REFERENCES

- Attard NJ, Zarb GA. Immediate and early implant loading protocols: a literature review of clinical studies. *J Prosthet Dent* 2005;94(3):242-58.
- Brochu JF, Anderson JD, Zarb GA. The influence of early loading on bony crest height and stability: a pilot study. *Int J Prosthodont* 2005;18(6):506-12.
- Chiapasco M. Early and immediate restoration and loading of implants in completely edentulous patients. *Int J Oral Maxillofac Implants* 2004;19 Suppl:76-91.
- Mericske-Stern R, Oetterli M, Kiener P, Mericske E. A follow-up study of maxillary implants supporting an overdenture: clinical and radiographic results. *Int J Oral Maxillofac Implants* 2002;17(5):678-86.
- Misch CE, Degidi M. 5-year prospective study of immediate/early loading of fixed prostheses in completely edentulous jaw with a bone quality-based implant system. *Clin Implant Dent Relat Res* 2003;5(1):17-28.
- Payne AG, Tawse-Smith A, Thomson WM, Duncan WD, Kumara R. One-stage surgery and early loading of three implants for maxillary overdenture: a 1-year report. *Clin Implant Dent Relat Res* 2004;6(2):61-74.
- Raghoobar GM, Friberg B, Grunert I, Hobkirk JA, Tepper G, Wendelhag I. 3-year prospective multicenter study on one-stage implant surgery and early loading in the edentulous mandible. *Clin Implant Dent Relat Res* 2003;5(1):39-46.
- Raghoobar GM, Schoen P, Meijer HJ, Stellingsma K, Vissink A. Early loading of endosseous implants in the augmented maxilla: a 1-year prospective study. *Clin Oral Implants Res* 2003;14(6):697-702.



Osteomorphogenesis biostimulated by CMF, Combined Magnetic Fields

M. Corigliano¹, **S. Rossi²**, F. Crescentini², A. Giovanetti², S. Di Carlo²

¹International Academy of Implantoprosthesis and Osteoconnection; Rome, Italy

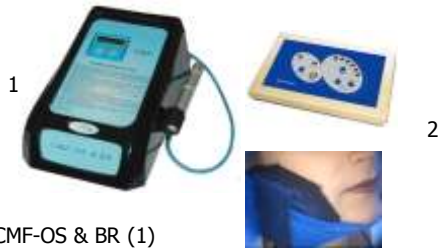² University of Rome Sapienza, Italy



Introduction – It has been clearly proved by Ludwig through Fourier’s analysis [Ludwig,1993] that ultraweak signals are easily recognized compared with the background noise if they present a "pattern":the signals the living matter is able to recognized among a variety of interferential signals, are highly complex, that is they are made up of different frequency bands. Infact the complex signal reaches the biological system as a repetition of weak signals, but connected among them in a fixed pattern, and it is the repetition of this pattern that distinguish the "true signal" from the background noise. The action of the CMF identifies as the sum of the effects of superimposed continous and pulsed magnetic fields on biological systems.On the bone tissue is possible to obtain a neo-osteomorphogenesis increasing the gene expression of the morphogenetic proteins and modulating the osteoclastogenetic proteins action. The same results we can obtain on soft tissue.
The target of our clinical trial "in vivo" can demonstrate the effects of Combined Magnetic Field on the bone tissue in oral implantology.

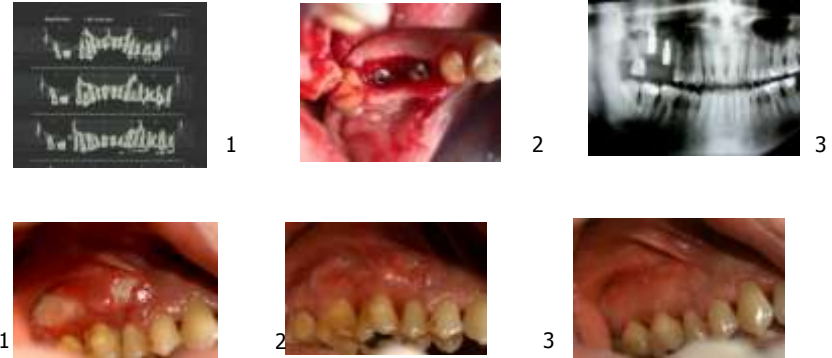
Materials: CMF-OS &BR Inductor of CMF multifrequential and presequential with continous magnetic fields. Frequency from 1 to 80Hz. Amplitude from 1 a 100µT and field amplifier/concentrator. TME, inductor of bifrequential field.:Amplitude from 5 a 50G for domiciliary use.
Induction Method: 6 inductions with CMF every 3 days for 12 min/die and TME domiciliary 30min X 2/die X 45 days.(inductors MFI, Italy)

Methods: 458 patients of both genders, aged between 35 and 72 yrs, underwent implant surgery associated with GBR, according to the protocol of the PBR implant system. 1024 fixtures were inserted by means of the TMI® implant system (Pressing Dental, RSM).
The MET and CMF (MFI Italy) were applied to all patients for 74 days.
Osteogenesis was radiologically controlled after 30, 60, 90, and 120 days. All implants were loaded in 120 days.



CMF-OS & BR (1)
TME (2) MFI Production

Fig..1 Dental-Scan
Fig.2 Implants
Fig.3 RX results
After 45 days
CMF-TME therapy



Soft Tissues: unsuccessfull gengivoplasty. Fase1 date 11.04.2007, (2)date 11.18.2007, (3)12.06.2007.
CMF treated 6 X 12 min induction, sequenced every 3days

Results: All those who underwent implant therapy with GBR, and were treated with the combination of MET and CMF, showed complete mineralization in a shorter period of time than that commonly reported in these cases.

Stimulated morphogenetic proteins gene expression and modulation of osteoclastogenesis by CMF induction:
FGF-2, FGFai, Angiopoietin,Trombopoietin, EGF,Connexin 43
Cox-1 e Cox-2, BMP-2, BMP-4, c-myc e c-fos,G-protein,Collagen I, osteocalcin,
Signal Molecules: Erk 1/2,CREB,IRS-1,eNOS
Cytokine: IL1, TNFα,TNFβ,TGka,TGFβ,PDGF,IGF-1,IGF-2,FGF
Osteoclastogenesis Modulators: OPG,Rank, RANKL, M-CSF,PGE2
Enzymes:Cytocrome-Ossidase,Na,K-ATPase, hsp70, ornithine decarboxilase, adinylate-cyclase, protein kinase C
Densification Proteins and ions: ,Osteocalcin, Procollagen,ionized calcium, ALP,Estrogen-receptor system, Proteoglycans, Collagen III,TP1 TPIII

Conclusions: The combined use of MET and CMF, together with the PBR implant system, can ameliorate and strengthen the physiological mechanisms of bone reparation.

Ludwig W: Magneitic Field Therapy. In: Alternative Medicine. Future Medicine Publishing, Washington (1993)
McLeod BR, Liboff AR. Dynamic characteristics of membrane ions in multifield configurations of low-frequency electromagnetic radiation.Bioelectromagnetics. 1986;7(2):177-89
Blank M, Goodman R. Electromagnetic fields may act directly on DNA.Department of Physiology, Columbia University, New York, New York 10032, USA. mb32@columbia.edu; J Cell Biochem. 1999 Dec 1;75(3):369-74.



Usò degli impianti TMI nella Riparazione Ossea Primaria nei post-estrattivi a carico immediato.

S. Rossi, A. Giovannetti, M. Corigliano, S. Di Carlo.

Università di Roma "Sapienza", Dipartimento di Scienze Odontostomatologiche
Insegnamento di Protesi Dentaria I: Titolare Prof. S. Di Carlo

INTRODUZIONE

La terapia implanto-protetica ha rappresentato negli ultimi decenni uno dei maggiori progressi ottenuti in ambito odontostomatologico. L'avvento dell'osteointegrazione ha radicalmente modificato l'approccio alla terapia implantare portando allo sviluppo di protocolli chirurgici e protesici standardizzati. La riduzione o l'eliminazione dell'intervallo di tempo tra l'inserimento della fixture e la sua protesizzazione ha rappresentato quindi uno dei principali temi di ricerca in campo implantologico.

MATERIALIE METODI

Lo scopo di questo lavoro è dimostrare i vantaggi offerti dalla Riparazione Ossea Primaria (R.O.P.) nell'applicazione di uno o più elementi a supporto implantare con carico immediato secondo un meccanismo di guarigione ossea naturale per prima intenzione. Per carico immediato si intende l'applicazione di carichi (o forze) agli impianti subito dopo il loro posizionamento.

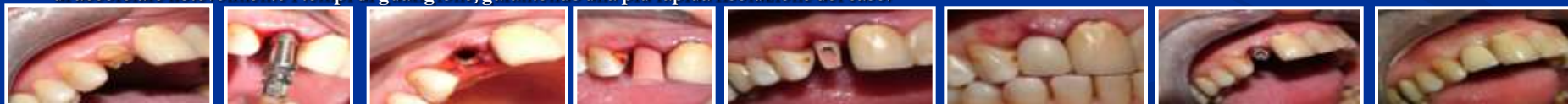Diversi autori hanno parlato però di carico immediato anche quando l'applicazione di forze non è immediata, ma avviene dopo 24 ore, 72 ore, o anche a distanza di una settimana. Tale protocollo è in grado di offrire il vantaggio di ridurre le procedure chirurgiche e i tempi di attesa per la riabilitazione protesica provvisoria senza la necessità di dover ricorrere a protesi rimovibili. Grazie all'applicazione del restauro provvisorio l'osso risulta uniformemente ma non eccessivamente caricato ed è noto come il carico occlusale induca una microstimolazione capace di incrementare qualitativamente e quantitativamente il processo di osteogenesi. La R.O.P. è un meccanismo di guarigione ossea per prima intenzione mediante il quale due segmenti ossei traumatizzati, con frattura semplice, si consolidano in un periodo fisiologico di sei settimane per rimodellamento Haversione e l'applicazione di osso primario direttamente sull'impianto senza passare attraverso le fasi: osteoclastica-macrofagica, connettivale, di mineralizzazione della trama connettivale così come previsto dai protocolli per l'ottenimento dell'osteointegrazione. L'osteointegrazione necessita di 90 giorni di tempo per l'applicazione di un carico funzionale corretto, infatti i tessuti traumatizzati riparano e si organizzano per seconda intenzione con una sequenza di sette fasi. L'osteocolessione è un processo di riparazione ossea per prima intenzione che si svolge in tre passaggi ed in 42 giorni. L'impianto a R.O.P. TMI® è caratterizzato da un aspetto radiceforme sviluppato sul principio dell'accoppiamento conico tra impianto ed un sito ricevente di identica forma e dimensioni, con un collo cilindrico e liscio di 2,5 mm di altezza ed un corpo a conicità progressiva dotato di spire automaschianti a passo fisso. Il corpo implantare è attraversato da 6 canali verticali i quali evitano la compressione dei liquidi biologici depositati all'interno della cavità consentendone il deflusso.

RISULTATI

Il termine di R.O.P. risulta del tutto giustificato in implantoprotesi odontoiatrica perché: la riparazione ossea che avviene intorno agli impianti TMI® presenta gli stessi quadri istologici con un netto miglioramento dei tempi di guarigione. Garantisce l'attivazione delle cellule ossee quiescenti, non è preceduta da riassorbimento né da formazione di tessuto cartilagineo o connettivo è quindi "diretta".

CONCLUSIONI

Questa ricerca è iniziata nel gennaio 2006, sono stati inseriti 82 impianti: 51 nel mascellare superiore e 31 nella mandibola con lunghezze comprese tra 13 e 15 mm. e Ø tra 3,7 a 4,7 mm. Al termine di questa prima fase di sperimentazione tutti gli impianti hanno raggiunto una valida osteocolessione risultando una percentuale di successo del 100%. Va tuttavia sottolineato che ancora tutti gli impianti non sono stati finalizzati protesicamente. Possiamo affermare che gli impianti a R.O.P. TMI® consentono di accorciare notevolmente i tempi di guarigione, garantendo una più rapida risoluzione del caso.



BIBLIOGRAFIA

1. Schenk R.K. : *Histologie der Primären Knocheilung*. Verh. Dtsch ges pathol. 1974; 54: 8-12.
2. Corigliano M, Vrespa G, D'Addona A, Casolo F. : *Impianto a guarigione primaria*. Dental Cadmos 1994; 11: 60-72.
3. Piattelli A, Paolantonio M, Corigliano M, Scarano A. : *Immediate loading of titanium plasma-sprayed screw-shaped implants in man: a clinical and histological report of two cases*. J Periodontol 1997;68:591-597.
3. Corigliano M, Barlattani A, Gargari M, Otrria L, Andreana S. : *La riparazione ossea primaria in implantoprotesi; possibilità, tecnica ed applicazioni*. Quint Int 2002; 9/10: 359-370.
4. Cooper LF, Rahman A, Moriarty J, Chaffee N, Sacco D. : *Immediate mandibular rehabilitation with endosseous implants: simultaneous extraction, implant placement and loading*. Int J Oral Maxillofac Implants 2002;17(4):517-25.
5. Gherlone E, Albano F, Vrespa G, Falegatti G, Capuano A. : *Carico immediato su impianti post estrattivi immediati*. Implantologia 2004;1:25-37.
6. Forabosco A, et al. : *Impianti postestrattivi a carico immediato*. : Doctor Os 2006;17(1):188-190



The immediate load in a post - extractive implant

S. ROSSI¹, M. CORIGLIANO², S. DI CARLO¹, and G. POMPA¹

¹University of Rome Sapienza, Italy,

²International Academy of Implantoprosthesis and Osteoconnection, Rome, Italy

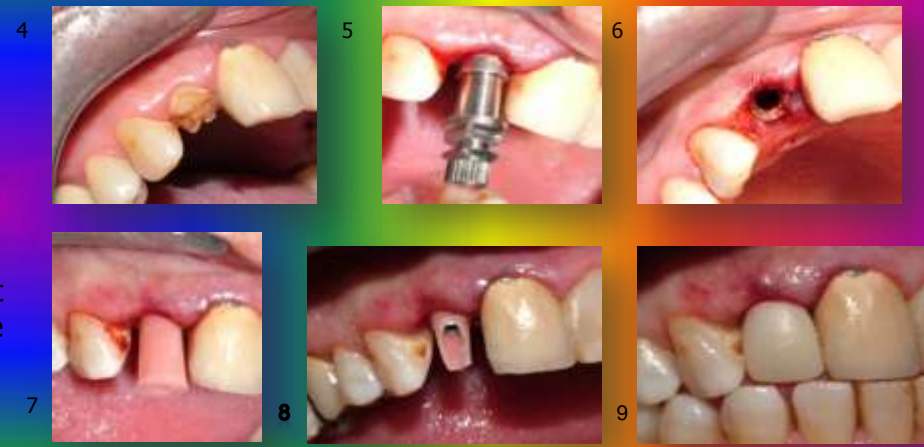
Objectives: *The aim of the present study is to evaluate the effects of TMI® (Pressing Dental, RSM) implants in comparison with the post-extraction protocol in the immediate load.*

Methods: We selected 138 individuals: 79 men (mean age, 58.33 yrs) and 59 women (mean age, 43.8 yrs). Of these, 50 were smokers, and 32 had periodontal disease. We extracted 140 teeth: 54 superior laterals, 33 superior canines, 28 inferior centrals, and 27 inferior laterals. The positioned implants were: 136 for singular extraction, 2 for double extraction (of adjacent elements), and 2 for the extraction of non-adjacent elements. Eighty-four implants were positioned in the upper jaw and 56 in the lower jaw (52 implants Ø 3.7, 46 implants Ø 4.2, and 42 implants Ø 4.7; length from 13 to 15 mm). All implants were temporarily loaded with non-functional crowns for 75 days.



Fig.1 Pilot Drill
Fig.2 Osteotom "UNICA"
Fig.3 Implant

Fig.4 Fractured Tooth
Fig.5 Fitting of the implant
Fig.6 Fitted implant
Fig.7 Temporary abutment
Fig.8 Prepared abutment
Fig.9 Temporary crown



Results: The experimental period has lasted 24 months thus far without showing any failure. Before cementation of each final restoration, we took periapical x-rays using a digital x-ray system (Den Optix, Gendex, Dentsply Int).

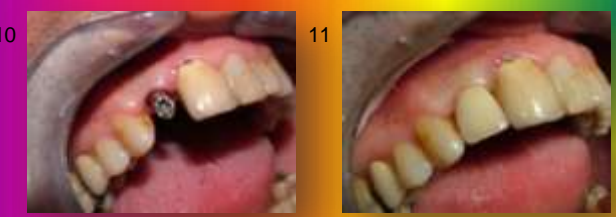

Fig.10 Final abutment
Fig.12 Ceramic crown

Conclusions: The clinical and radiographic results showed that the treatment is completely effective if the strict inclusion criteria are suitably applied.

1. Schenk R.K. : *Histologie der Primären Knocheilung. Verh. Dtsch ges pathol.* 1974; 54: 8-12.
2. Corigliano M, Vrespa G, D'Addona A, Casolo F. : *Impianto a guarigione primaria. Dental Cadmos* 1994; 11: 60-72.
3. Piattelli A, Paolantonio M, Corigliano M, Scarano A. : *Immediate loading of titanium plasma-sprayed screw-shaped implants in man: a clinical and histological report of two cases. J Periodontol* 1997;68:591-597.
3. Corigliano M, Barlattani A, Gargari M, Ottria L, Andreana S. : *La riparazione ossea primaria in implantoprotesi; possibilità, tecnica ed applicazioni. Quint Int* 2002; 9/10: 359-370.
4. Cooper LF, Rahman A, Moriarty J, Chaffee N, Sacco D. : *Immediate mandibular rehabilitation with endosseous implants: simultaneous extraction, implant placement and loading. Int J Oral Maxillofac Implants* 2002;17(4):517-25.
5. Gherlone E, Albano F, Vrespa G, Falegatti G, Capuano A. : *Carico immediato su impianti post estrattivi immediati. Implantologia* 2004;1:25-37.
6. Forabosco A, et al. : *Impianti postestrattivi a carico immediato. Doctor Os* 2006;17(1):188-190.